

## Aortic Coarctation: Evaluation with Computed Tomography Angiography in Pediatric Patients

MOHAMED ZAKI, M.D. and MOHAMED HASSAN, M.D.

The Department of Radiology, Faculty of Medicine, Sohag University, Egypt

### Abstract

**Background:** Aortic coarctation is a congenital narrowing of the aorta. Computed tomography angiography is used to detect aortic coarctation and determine its extent and severity.

**Objective:** To assess pediatric aortic coarctation by computed tomography (CT) angiography.

**Material and Methods:** This study included eighteen patients (10 males and 8 females) who were clinically diagnosed to have coarctation. Both echocardiography and CT angiography were done to all patients. Axial, multi-planar and volume rendering reconstructions are done to all patients. The presence, site and extent of coarctation are reported. Other cardiovascular anomalies and findings are also registered. The results of both CT angiography and echocardiography are compared to each other.

**Results:** Seventeen from the examined group were had coarctation of the aorta. The residual patient had double aortic arch. The sensitivity of CT angiography for diagnosis of the coarctation of the aorta was (100%) which was higher than that of Doppler echocardiography (82%). The sensitivity of CT angiography for the assessment of cardiac defects was (72%) which was lower than that of Doppler echocardiography (100%).

**Conclusion:** CT angiography with reconstruction techniques is a valuable imaging modality for pediatric patients with coarctation of the aorta.

**Key Words:** Aortic coarctation – CT angiography – Doppler echocardiography.

### Introduction

**COARCTATION** of the aorta is not uncommon anomaly of the aorta. Patients with coarctation of the aorta have high risk of complications. So, early repair in the pediatric age group is mandatory to save these patients [1-4]. Coarctation of the aorta commonly observed at the aortic isthmus, between

the left subclavian artery and the ductus. Usually coarctation of the aorta is suspected clinically and may be diagnosed by echocardiography. Nowadays, with the steady effort to improve the performance of CT, new generations of excellent CT machines with multiple rows of detectors came to the field of imaging. These scanners are so rapid to be helpful in pediatric group with congenital cardiovascular defects. CT angiography with its reconstructions techniques were reported in many studies to evaluate the morphology of coarctation of the aorta, especially to assess the location, degree, and length of the narrowing; presence of collateral circulation; relationship to the left subclavian artery; and also associated cardiovascular abnormalities [5-7]. It is beneficial to have accurate information about each of these parameters to help the surgeon for early repair and guard against complications [8-10].

The objective of our work was to evaluate the coarctation of the aorta in pediatric age group by CT angiography and their reconstructions techniques.

### Material and Methods

Our study included 18 patients (10 males and 8 females; age range, 5 months to 11 years with the mean of 6.4 years). All patients are clinically diagnosed as coarctation of the aorta in Sohag University Hospital from June 2009 to May 2014. The patients presented with variable symptoms and signs (dyspnea, chest pain, headache, upper limb hypertensions, weak femoral pulse, etc). Patients who had contraindications to contrast medium are excluded from the study.

#### Abbreviations:

CT : Computed tomography.  
LSA : Left subclavian artery.

VSD : Ventricular septal defect.  
ASD : Atrial septal defect.

**Correspondence to:** Dr. Mohammed Zaki,  
[E-mail: zakifm2000@yahoo.com](mailto:zakifm2000@yahoo.com)

Oral and written informed consent was taken from the patients parents in accord with the ethical standards of the institutional committee.

Echocardiography was done to all patients. Then; patients were prepared for CT angiography. Intravenous lines were established to all patients. Patients below 5 years were sedated by oral administration of chloral hydrate (50mg/kg body weight) but patients above 5 years were cooperated without sedation (just presence of one of he parents close to the patient after shielding).

#### *CT technique and imaging processing:*

CT angiography was done to all patients using 8-detectors scanner (General Electric Medical Systems, USA). The patient lies supine with quiet respiration and examined from the base of the neck to the diaphragm. Field of view (FOV) was set to 250X250mm. The tube voltage was tailored according to the weight of the patient. Slice thickness from 1.25mm to 2mm. Non-ionic contrast medium (2ml/kg) was injected into upper limb vein at a flow rate of 1.5-3ml/s (Omnipaque 300) with the aid of an injection pump to ensure satisfactory vessel opacification in the entire volume examined. Real-time bolus tracking technique was performed. Usually the examination is started 3-5 seconds after region of interest at the ascending aorta reaching attenuation of 150HU.

Axial, sagittal, coronal, and oblique multi-planar images were reviewed for all cases. Volume-rendering algorithms were used to show the vascular surfaces. Reconstructed images were generated at a separate workstation. The images were selected so that the aorta and its branches, pulmonary arteries, and superior vena cava were always seen and displayed in a similar fashion for all cases. CT images were evaluated for the site, extent and degree of coarctation of the aorta. Aortic coarctation was defined as greater than 25% decrease in vessel diameter, either focal or diffuse. The degree of stenosis was considered severe if the ratio of the coarctation diameter to the distal descending aortic diameter was less than 50%. The extent of the coarctation was considered short if the length of the narrowed aortic segment was less than 5mm and long if the length was more than 5mm. The presence of additional cardiac defects such as atrial septal defects, ventricular septal defects and patent ductus arteriosus was evaluated. Other extra-vascular chest lesions were also reported.

CT angiography results were compared with that of echocardiography.

## Results

Seventeen of our 18 patients have coarctation of the aorta Figs. (1-6). The 18<sup>th</sup> patient was double aortic arch Fig. (7). Two coarctation lesions are missed on reviewing the axial images, however these are well delineated in the multi-planar and volume rendering images. The coarctation was severe in 12 patients. The site of coarctation was proximal to the left subclavian artery in 3 patients and distal to the left subclavian artery in 14 patients. The overall sensitivity in detecting coarctation by all reviewing images was 100%. Three coarctation lesions are missed at echocardiography giving a sensitivity of 82%. Associated cardiac anomalies were also observed. Ventricular septal defect is noted in 3 cases by CT Fig. (2) but observed in 4 patients by echocardiography. Also atrial septal defect is noted in 2 patients Fig. (2) but was seen in 3 patients by echocardiography. The overall sensitivity of CT in detecting cardiac anomalies is 72% and echocardiography is 100%. Patent ductus arteriosus was seen in 6 patients and also seen by echocardiography in all patients. Ascending aortic aneurysmal dilatation was observed by CT in our series in 2 patients without dissection flap Fig. (5). Collateral vessels are seen by CT angiography in 5 cases Fig. (1). The dilated internal mammary arteries, posterior intercostal arteries and thoracoacromial arteries are clearly seen by CT angiography. As regards other chest lesions detected by CT; we detect two patients with pleural effusion and one patient with pneumonia (Table 1).

Table (1): CT findings detected in 18 patients.

CT finding	Number of patients
Coarctation of the aorta	17
Double aortic arch	1
Severe coarctation	12
Coarctation proximal to LSA	3
Coarctation distal to LSA	14
Ventricular septal defect	3
Atrial septal defect	2
Patent ductus arteriosus	6
Ascending aortic aneurysm	2
Collateral vessel formation	5
Pleural effusion	2
Pneumonia	1

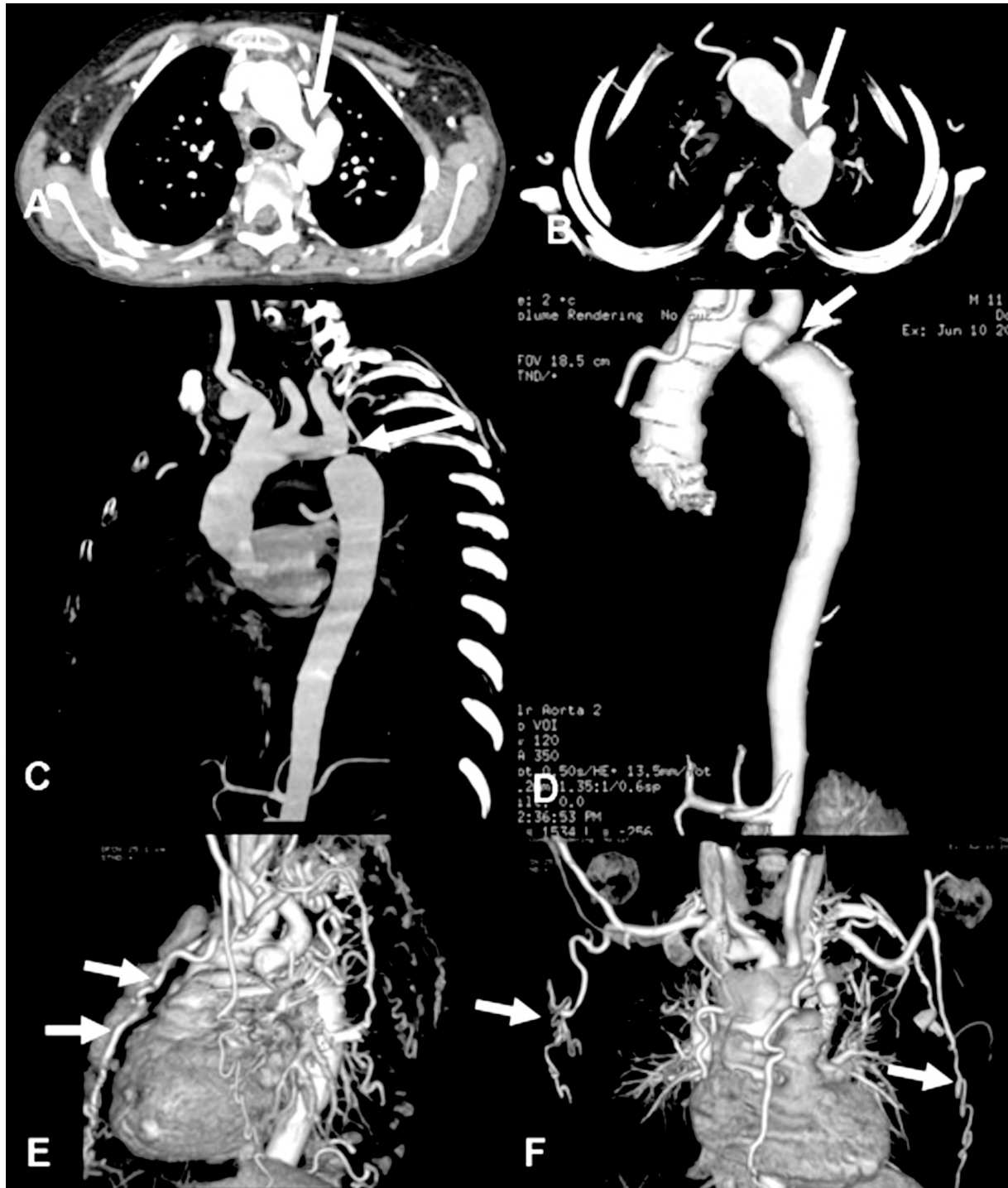


Fig. (1): CT images of a 11-year-old boy with severe coarctation of the aorta.

- (A): Axial contrast enhanced image showing the site of coarctation (arrow).
- (B): Axial multi-planar reformatted image showing the site of coarctation (arrow).
- (C): Sagittal oblique multi-planar reformatted image reveals severe localized coarctation (arrow).
- (D): Left lateral 3D volume rendering image demonstrating the site of coarctation (arrow).
- (E): Left lateral volume rendering image showing the enlarged internal mammary artery (small arrows).
- (F): Anterior volume rendering image showing the dilated descending scapular arteries (small arrows).

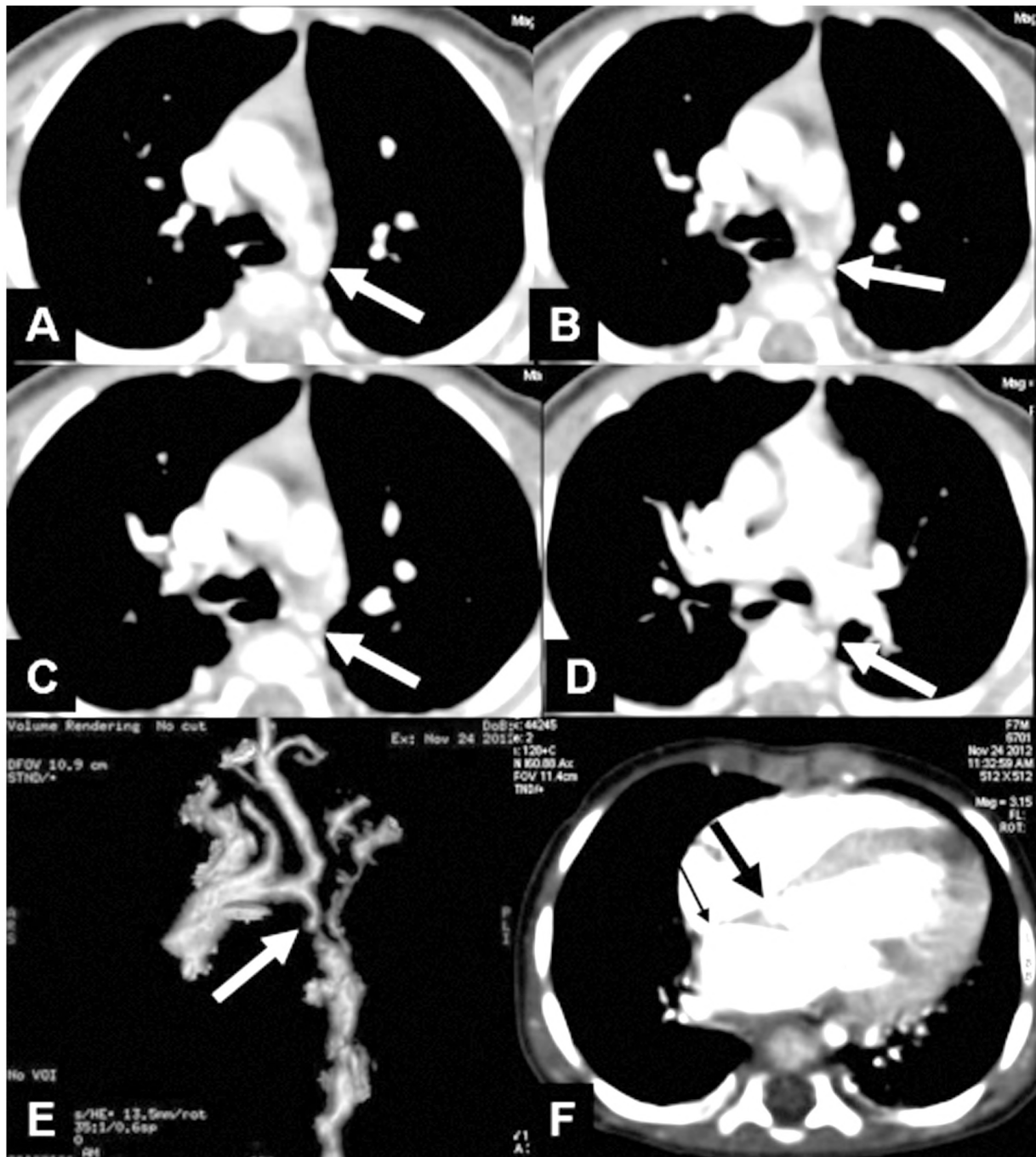


Fig. (2): CT images of a 7-month-old girl with severe long coarctation of the aorta.

- (A, B, C & D): Axial contrast enhanced images showing the markedly narrowed aortic lumen (arrows).  
 (E): Left lateral volume rendering image showing the site of coarctation (arrow).  
 (F): Axial contrast enhanced images demonstrating the 4 chambers of the heart. ASD (thin black arrow) and VSD (thick black arrow) are seen.

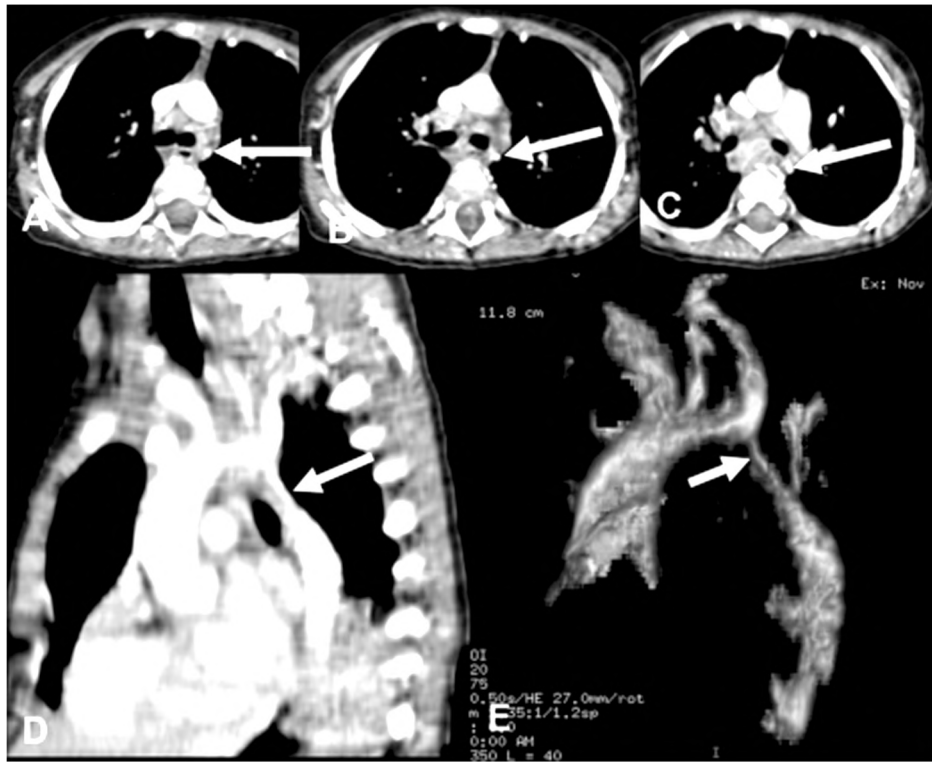


Fig. (3): CT images of a 2-year-old boy with severe long coarctation of the aorta distal to the left subclavian artery. (A, B, & C): Axial contrast enhanced images showing the markedly narrowed aortic lumen all-over the multiple images. (D): Sagittal oblique multi-planar reformatted image demonstrating the site of coarctation (arrow). (E): Left lateral volume rendering image showing the site of coarctation (arrow).

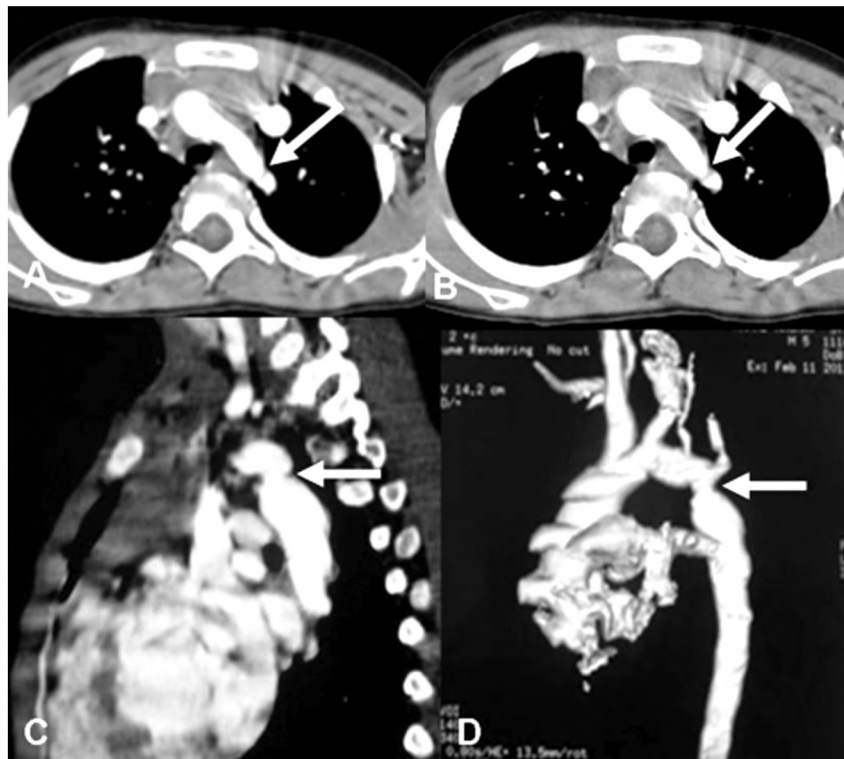


Fig. (4): CT images of a 5-year-old boy with coarctation of the aorta distal to the left subclavian artery. (A & B): Axial contrast enhanced images showing the site of coarctation (arrows). (C): Sagittal reformatted image demonstrating the site of coarctation (arrow). (D): Left lateral volume rendering image showing the site of coarctation (arrow).

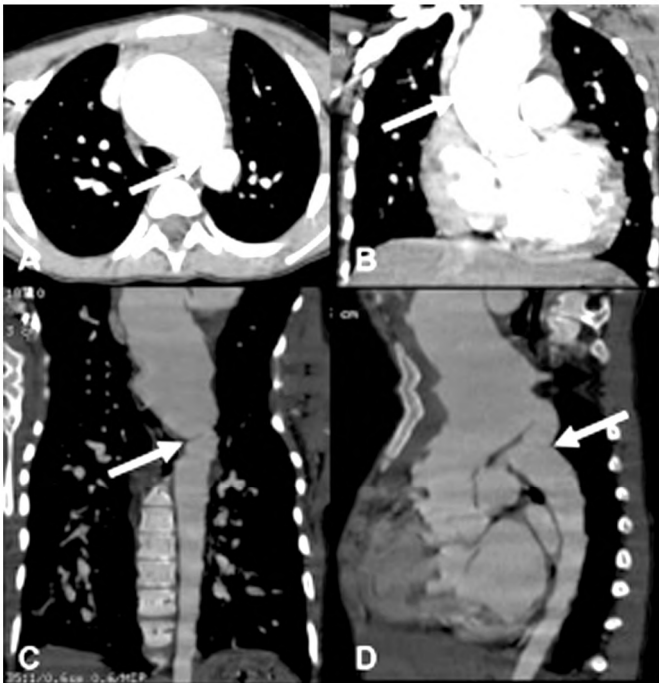

Fig. (5): CT images of a 8-year-old girl with coarctation of the aorta.

- (A): Axial contrast enhanced image showing the site of coarctation (arrow).
- (B): Coronal multi-planar reformatted image showing aneurysmal dilatation of the ascending aorta (arrow).
- (C): Coronal multi-planar reformatted image reveals the site of coarctation (arrow).
- (D): Sagittal multi-planar reformatted image demonstrating the site of coarctation (arrow).

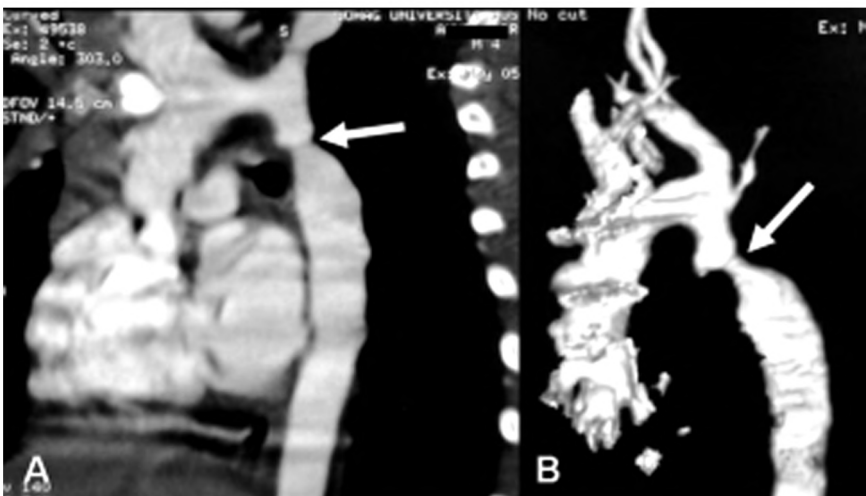


Fig. (6): CT images of a 4-year-old boy the aorta distal to the left subclavian artery.

- (A): Sagittal oblique multi-planar reformatted image demonstrating the site of coarctation (arrow).
- (B): Left lateral volume rendering image showing the site of coarctation (arrow).

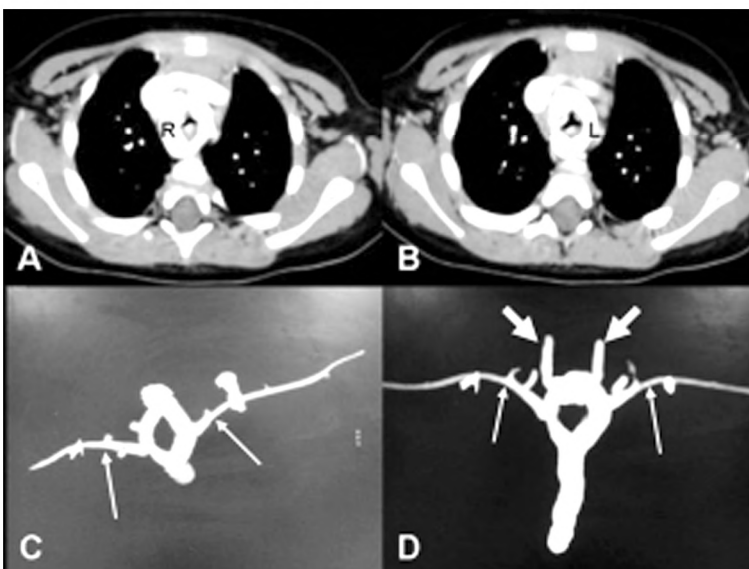


Fig. (7): Double aortic arch in 9-year-old girl.

(A&B): Axial contrast enhanced CT images obtained at mid-tracheal level show both right (R) and left (L) limbs of double aortic arch surrounding the trachea and esophagus. At this level, bilateral tracheal compression is present.

(C&D): Volume rendering 3D CT images showing demonstrating clearly the double aortic arch with the right and left common carotid arteries (thick arrows) and right and left subclavian arteries (thin arrows) arising from the double aortic arch.

## Discussion

Pediatric imaging is a real challenge for radiologist especially coarctation of the aorta. Here is a need of a non-invasive, rapid and high resolution modality to delineate the presence, site, degree of coarctation. Moreover collateral vessels formations are important to be characterized in patient with coarctation of the aorta. Conventional aortic angiography was an excellent modality to examine the aorta but it is invasive method with high possibility of complications [11].

With the use of contrast enhanced MRI we could diagnose many thoracic abnormalities. MRI could detect the presence of coarctation of the aorta with its collaterals. MRI could also characterize associated cardiac anomalies with cine imaging [12,13]. However MRI is expensive, not generally available and it is time consuming which is not suitable for pediatric.

Echocardiography is the modality of choice to examine cardiac defects (100% in our study) and possible associated extra-cardiac anomalies. It is rapid, safe and available modality. However three cases of coarctation of the aorta are missed in this study by using echocardiography. Our results are consistent with other reported studies [14,15]. Poor acoustic window due to lung and thoracic cage bone are the causes of the negative results of echocardiography.

CT angiography with its reconstructions techniques became the modality of choice in examining the coarctation of the aorta in pediatric patients. It is rapid and non invasive with high resolution images [1,15]. CT angiography has a sensitivity of 100% for detecting coarctation of the aorta and higher than that of echocardiography. As regards cardiac defects; CT has lower sensitivity (72%) than echocardiography (100%). These results are consistent with other previously reported results [1,9,14,15].

Collateral vessels identification is important before surgery to guard against complication. The collateral vessels are commonly seen with coarctation of the aorta especially with severe ones. The collateral vessels mostly come from the branches of the subclavian arteries above the coarctation and provide blood to the region below the coarctation. The main collateral vessels include the pathway from the internal mammary artery through the intercostal arteries to the post-coarctation descending thoracic aorta. Also, from the thyro-cervical and costo-cervical trunks through the thoraco-acromial and descending scapular arteries to the

post-coarctation descending thoracic aorta. Lastly; from the vertebral artery through the anterior spinal artery and intercostal arteries to the post-coarctation descending thoracic aorta [16]. CT angiography could delineate collateral vessel formation in 5 patients in our study.

Our study has limitations. First; the series included small number of patients (18 patients). However they are informative and could observe and diagnose all cases of coarctation especially with multi-planar reconstructions and volume rendering techniques. Second, the results of CT angiography and color Doppler echocardiography are not compared with the surgical results. Actually this is because most of the pediatric patients with coarctation of the aorta were referred to more specialized hospitals in Cairo or in Aswan. Also CT radiation hazards must put in mind and rationale to decrease the dose of radiation must be used in pediatric patients.

## Conclusion:

Pediatric patients with coarctation of the aorta can be excellently evaluated by CT angiography. This modality is non-invasive, rapid with high spatial resolution. Recent advances in CT reconstruction techniques help in the better characterization of aortic coarctation. It can determine the extent and degree of coarctation. It can also exclusively delineate the origin and extent of collaterals. Other extra-vascular chest lesions such as pneumonia and pleural effusion in pediatric patients are well diagnosed by the use of CT. So; CT angiography is the modality of choice to examine pediatric patients with coarctation of the aorta especially with the use of low dose rationale.

## References

- 1- LEE E.Y., SIEGEL M.J., HILDEBOLT C.F., et al.: MDCT evaluation of thoracic aortic anomalies in pediatric patients and young adults: Comparison of axial, multiplanar, and 3D images. *A.J.R. Am. J. Roentgenol.*, 182: 777-84, 2004.
- 2- HU X.H., HUANG G.Y., PA M., et al.: Multidetector CT angiography and 3D reconstruction in young children with coarctation of the aorta. *Pediatr. Cardiol.*, 29: 726-31, 2008.
- 3- WESTABY S., PARNELL B. and PRIDIE R.B.: Coarctation of the aorta in adults. *J. Cardiovasc. Surg.*, 28: 124-7, 1987.
- 4- FIXLER D.E.: Coarctation of the aorta. *Cardiol. Clin.*, 6: 561-71, 1998.
- 5- ODDONE M., GRANATA C., VERCELLINO N., et al.: Multimodality evaluation of the abnormalities of the aortic arches in children: Techniques and imaging spectrum with emphasis on MRI. *Pediatr. Radiol.*, 35: 947-60, 2005.



- 6- GOO H.W., PARK I. S., KO J.K., et al.: Computed tomography for the diagnosis of congenital heart disease in pediatric and adult patients. *Int. J. Cardiovasc. Imaging*, 21: 347-65, 2005.
- 7- LESCHKA S., OECHSLIN E., HUSMANN L., et al.: Pre and postoperative evaluation of congenital heart disease in children and adults with 64-slice CT. *Radiographics*, 27: 829-46, 2007.
- 8- OGUZ B., HALILOGLU M. and KARCALTINCABA M.: Paediatric multidetector CT angiography: Spectrum of congenital thoracic vascular anomalies. *Br. J. Radiol.*, 80: 376-83, 2007.
- 9- TURKVATAN A., OZDEMIR P.A., OLCER T., et al.: Coarctation of the aorta in adults: Preoperative evaluation with multidetector CT angiography. *Diagn. Interv. Radiol.*, 15 (4): 269-74, 2009.
- 10- FRUSH D.P.: Thoracic cardiovascular technique and applications. *Pediatr. Radiol.*, 39 (Suppl.): 464-70, 2009.
- 11- GODART F., LABROT G., DEVOS P., et al.: Coarctation of the aorta: Comparison of aortic dimensions between conventional MR imaging, 3D MR angiography, and conventional angiography. *Eur. Radiol.*, 12: 2034-9, 2002.
- 12- DIDIER D., SAINT-MARTIN C., LAPIERRE C., et al.: Coarctation of the aorta: Pre and postoperative evaluation with MRI and MR angiography; correlation with echocardiography and surgery. *Int. J. Cardiovasc. Imaging*, 22: 457-75, 2006.
- 13- KELLENBERGER C.J., YOO S.J. and BÜCHEL E.R.: Cardiovascular MR imaging in neonates and infants with congenital heart disease. *Radiographics*, 27: 5-18, 2007.
- 14- KAMAL O.A. and AHMED M.M.: Role of multidetector computed tomography (MDCT) angiography in preoperative assessment of coarctation of the aorta in pediatric patients and young adults. *The Egyptian Journal of Radiology and Nuclear Medicine*, 42: 297-303, 2011.
- 15- AL-AZZAZY M.Z., NASR M.S. and SHOURA M.A.: Multidetector computed tomography (MDCT) angiography of thoracic aortic coarctation in pediatric patients: Preoperative evaluation. *The Egyptian Journal of Radiology and Nuclear Medicine*, 45: 159-67, 2014.
- 16- PHILIPS R.R. and GORDON J.A.: Coarctation of the aorta. In: Bawm S., ed. *Abrams' angiography*. 4 th ed. Boston: Little Brown, 434-63, 1997.

## الملخص العربي

وقد هدفت الدراسة لتقييم دور تصوير الاوعية بالاشعة المقطعية بالكمبيوتر في حالات تضيق الاورطى عند الاطفال.

ولقد اشتملت الدراسة على ١٨ مريض، ولقد تم فحص كل الحالات بالموجات فوق الصوتية على القلب والاشعة المقطعية متعددة المقاطع بالصبغة على القلب والاعوية الدموية. ولقد تم عمل مقاطع مختلفة بالاشعة المقطعية وتم تحديد مكان وامتداد وشدة التضيق في الاورطى. ولقد تم تسجيل أى عيوب خلقية أخرى.

ولقد تم إكتشاف ١٧ حالة تضيق بالاورطى، وتم إكتشاف وجود إزدواج في قوس الاورطى في الحالة الثامنة عشر. ولقد كانت حساسية تصوير الاوعية بالاشعة المقطعية بالكمبيوتر في تشخيص حالات تضيق الاورطى عند الاطفال ١٠٠٪ أما بالنسبة لحساسية الموجات فوق الصوتية فكانت ٨٢٪. ولكن وجد أن حساسية الموجات فوق الصوتية أعلى في إكتشاف عيوب القلب الخلقية من الاشعة المقطعية.

ولقد أستنتج من هذه الدراسة أهمية تصوير الاوعية بالاشعة المقطعية بالكمبيوتر في حالات تضيق الاورطى عند الاطفال.